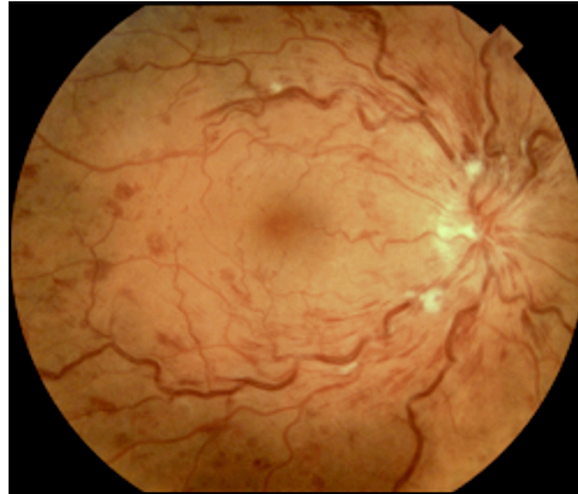

## New Treatment Paradigms in Managing Macular Edema in Retina Vein Occlusion

Retina vein occlusion is a common cause of sudden and chronic visual impairment, second only to diabetes in retinal vascular disease. This past year, the retina community has had the opportunity to review the results of four studies reporting on new therapies for retinal vein occlusion. The Retina Group of Florida was a key contributor to each of these studies, changing how we manage this debilitating disease.



New treatments have involved the injection of steroids or anti-VEGF agents.

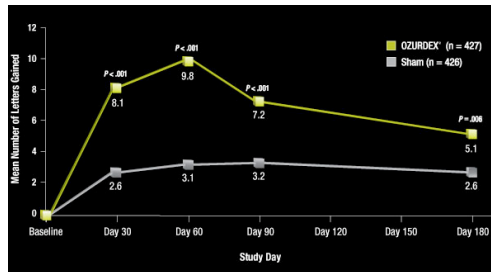
The **SCORE** study evaluated the effects intravitreal triamcinolone gel versus grid laser in BRVO and CRVO. The study found a beneficial effect in patients with CRVO versus observation at one and two years follow up. In BRVO, however, laser photocoagulation was still

For two decades, the **BVOS** (Branch Vein Occlusion Study) and **CVOS** (Central Vein Occlusion Study) have defined the standard of care for retinal vein occlusion therapy. The BVOS found grid laser for macular edema superior to observation, improving vision by 1.33 lines versus 0.23 lines with observation. By contrast, laser photocoagulation for perfused macular edema was not found to be of benefit in the CVOS, establishing observation as the standard of care for macular edema. Rubeosis, however, should be promptly treated with panretinal photocoagulation.

found to be superior with three years of follow up. 57% of patients receiving 4mg required glaucoma medications to control IOP.

The **Ozurdex** study compared the effect of a biodegradable intravitreal dexamethasone implant versus sham. Dexamethasone is 5x more potent

than triamcinolone. A comparison versus grid laser was not performed in this study. Both CRVO and BRVO demonstrated a visual benefit, which was most robust in the first two months but waned by months four and five. 15% had IOP >25 at Day 60.



*Continued on Page 2*

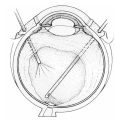
### Anti-Complement Study for Neovascular AMD

RGF continues to offer the latest cutting edge in treatment: we are currently recruiting for an anti-complement factor study for wet AMD that could potentially enhance the efficacy of anti-VEGF therapy.

The study is targeting patients that are not responded to current treatment with anti-VEGF agents such as ranibizumab (Lucentis) and bevacizumab (Avastin).

Patients enrolled in the study will continue to receive intravitreal ranibizumab, but will also receive an anti-complement factor for a 1:1 combination treatment.

Complement is involved in the critical steps that lead to apoptosis. Inhibition may be important in preventing cell death in dry & wet AMD.



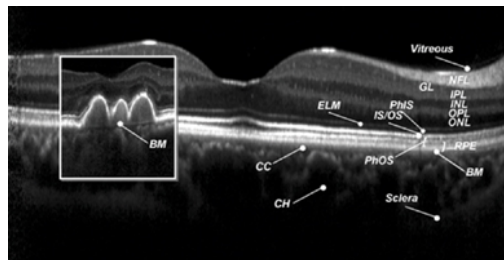
## Retinal Vein Occlusion Continued

**BRAVO** and **CRUISE** evaluated the ranibizumab's efficacy in treating CME in BRVO and CRVO, respectively. BRAVO data showed a mean gain in vision of 18.3 letters versus 7.3 letters in the sham group at 6 month follow up. CRUISE data demonstrated a mean gain in vision of 14.9 letters versus 0.8 letters in the sham group at 6 months follow up. Effects were sustained at one year follow up even though patients went to *prn* dosing for the second half of the study. In addition 60% of patients in the BRAVO study and nearly 50% of patients in the CRUISE study gained 3 lines of vision or more. There were no cases of ocular hypertension in either study.

Each of these new treatment options has both advantages and disadvantages. Although the visual gains are impressive with anti-VEGF treatment, monthly dosing still appears to be necessary initially. Steroids provide a robust visual response without the need for frequent dosing, but their effects wain after several months. In addition a high percentage of patients experience ocular hypertension and may develop cataract. The future may lie in combining these two drugs for a sustained effect without the need for monthly dosing. Laser still also plays an important role, particularly in BRVO patients as we learned from the SCORE study. After more than two decades of limited treatment options, the physicians of the Retina Group of Florida are excited about these new treatment approaches and now customize therapies based on the individual patient's presentation to maximize their visual outcome.

## RGF Offices Enhancing Efficiency

The offices space for our Fort Lauderdale and Plantation offices are being modified to help with patient flow. Spectral Domain (high-defintion) OCT continues to play



a critical role in the management of macular pathology, particularly in gauging response to treatment. The improved office layout will increase patient satisfaction by reducing wait time and allow for better transition from testing to treatment.

## Clinical Trials

### REGRESS

Combination Treatment: Anti-platelet derived growth factor & ranibizumab for Wet AMD

### RACE

Combination Treatment: Anti-complement & ranibizumab for wet AMD

Contact us at 954-776-6880, to speak with our study coordinator to refer a patient for a study.

## Physician Spotlight

Patrick E. Rubasamen, MD



Dr. Rubsamen brings a blend of academic and private practice experience to the Retina Group of Florida.

He received his medical degree from Univ. of TX, Southwestern before he relocated to Bascom Palmer for his ophthalmic and vitreoretinal training. He remained at Bascom Palmer as an Associate Professor for ten years, until joining RGF in 1999. Pat continues to be involved in the education of residents, fellows, and medical students.

His research interests and publication have involved diabetic retinopathy, retinal detachment, and ocular trauma.

In his spare time, Pat enjoys quality time with his wife and three sons, which includes lots of barbecue and surfing.